

Asian Fisheries Society, Manila, Philippines

# Histopathological and Electron Microscopic Studies of Gills and Opisthonephros of Rohu, *Labeo rohita* to Acute and Subchronic Aflatoxin B<sub>1</sub> Toxicity

P.K. SAHOO<sup>1</sup>, S.C. MUKHERJEE, A.K. JAIN<sup>2</sup> and A. MUKHERJEE<sup>2</sup>

<sup>1</sup>*Aquatic Animal Health Division  
Central Institute of Freshwater Aquaculture,  
Kausalyaganga, Bhubaneswar 751 002  
India*

<sup>2</sup>*Institute of Pathology  
Safdarjang Hospital Campus  
New Delhi-110 029  
India*

## Abstract

Morphological alterations of the gills and opisthonephros of rohu (*Labeo rohita*) following acute (0, 7.5 and 11.25 mg aflatoxin B<sub>1</sub> kg<sup>-1</sup> body weight) and subchronic (0, 1.25 and 2.5 mg aflatoxin B<sub>1</sub> kg<sup>-1</sup> body weight) single intraperitoneal (IP) exposure for a period of 10 and 90 days, respectively, were investigated by means of light and electron microscopy. The 10-days (IP) LD<sub>50</sub> of aflatoxin B<sub>1</sub> (AFB<sub>1</sub>) in rohu was 12.6 mg•kg<sup>-1</sup> of body weight, with a 95% confidence interval of 12.0-13.3 mg•kg<sup>-1</sup>. Fish exposed to high doses for 10 days revealed toxic changes varying from complete necrosis of gill lamellae to rupture of lamellar tips causing haemorrhages and epithelial cell separation forming edematous space alongwith primary lamellar hyperplasia. Prolonged exposure (90 days) at lower doses resulted in lamellar hyperplasia and fusion accompanied by epithelial cell edema. In opisthonephros of fish in both the trials had degenerative and necrotic changes in tubular epithelium. The interstitium of kidney had focal necrotic nodules in subchronic toxicity groups.

## Introduction

Aflatoxins are a group of extremely toxic fungal metabolites produced by *Aspergillus flavus*, *A. parasiticus* and *A. nomius*. The fungi are ubiquitous in nature and, under appropriate conditions of temperature and moisture,

grow on a variety of agricultural products. It is of great concern in many tropical countries because it commonly contaminates grains and feeds used as food ingredients for animals and man (Niyo 1989). In tropical and developing countries, although aquaculture shares more than 80% of total aquaculture production, it is common to observe pelleted feeds are generally and mostly improperly stored. The improper storing, packing and transport facilities, in conjunction with the high temperature and humidity in these areas, are conducive to fungal growth and the potential for aflatoxin production (Chavez-Sanchez et al. 1994). Out of 18 components of aflatoxins known so far, aflatoxin B<sub>1</sub>, the most potent and abundant toxic fraction present in feed, and is best known for its hepatotoxic, nephrotoxic, carcinogenic, mutagenic, teratogenic, cytotoxic and immunosuppressive properties (Sahoo et al. 1996), as a result of its incorporation into nucleic acids and proteins of the tissues of animals (Shank 1981). The presence of aflatoxin in feed stuffs beyond 15 ppm level has been recorded in India many times (Sahoo and Mukherjee 2001).

The toxicity of aflatoxins has been studied in different species of fish, such as salmonoids (Ashley and Halver 1963; Ashley 1967; Sinnhuber and Wales 1974; Hendricks et al. 1977), channel catfish (Jantrarotai and Lovell 1990; Jantrarotai et al. 1990), tilapia (Chavez-Sanchez et al. 1994), murels (Verma et al. 1989) and common carp (Svobodova and Piskac 1980). Susceptibility to the toxic effects of aflatoxins varies widely between species, with the rabbit, day-old duckling and the rainbow trout being the most sensitive animals and bird tested. The oral LD<sub>50</sub> of aflatoxin B<sub>1</sub> (AFB<sub>1</sub>) for rainbow trout is 0.5 mg•kg<sup>-1</sup> body weight and 0.81 mg•kg<sup>-1</sup> body weight via IP route (Halver et al. 1966 ; Bauer et al. 1969). The 10-d median lethal dose for IP-administered AFB<sub>1</sub> in channel catfish averaging 19 g is 11.5 mg•kg<sup>-1</sup> body weight (Jantrarotai et al. 1990).

Rohu, an important species of Indian major carps, is cultured in Indian subcontinent intensively. Till-date, the susceptibility of this species to AFB<sub>1</sub> is unknown. The liver is the target organ of this toxicity in rohu and the extent of damage to this organ along with other organs has also been reported earlier (Sahoo et al. 2001). The liver of rohu revealed massive necrosis due to acute toxicity and developed hepatocellular adenoma within a short single exposure period of 90 days in another subchronic toxicity trial (Sahoo et al. 2001). AFB<sub>1</sub> is excreted in urine and trunk kidney being the major excretory organ, is supposed to be affected by aflatoxins (Wogan 1966; Halver 1969; Jantrarotai et al. 1990). There is paucity of literature describing the toxic changes in gills due to aflatoxins (Ashley 1967). This paper describes the effects of aflatoxin B<sub>1</sub> on gills and opisthonephros of rohu during acute and subchronic AFB<sub>1</sub> toxicity.

## Materials and Methods

Rohu fingerlings (average length 14.2 ± 1.8 cm, weight 35.32 ± 4.14 g) were held in twelve 1000 l capacity plastic circular aquaria with provision for

continuous aeration. The basic physico-chemical water quality parameters viz., dissolved oxygen and pH were measured at 15 days intervals to maintain optimal levels (dissolved oxygen:  $5.65 \pm 0.72 \text{ mg}\cdot\text{l}^{-1}$ , pH:  $8.24 \pm 0.82$ , nitrites:  $0.015 \pm 0.009 \text{ mg}\cdot\text{l}^{-1}$ , ammonia:  $0.109 \pm 0.024 \text{ mg}\cdot\text{l}^{-1}$ ) throughout the period of the experiment. About 10% of water in the experimental tanks was replenished every 24 h. The water temperature during the experiment was 25–30°C. Dechlorinated (through adequate beforehand aeration) tap water was utilised for the study. A commercial pelleted feed for rohu fingerlings, free from aflatoxin contamination, was fed to fish @ 3% of their body weight, once daily throughout the experimental period.

The preliminary trials showed that the 10-d  $\text{LD}_{50}$  of  $\text{AFB}_1$  administered via IP injection would be between 7.5 and 20  $\text{mg}\cdot\text{kg}^{-1}$  of body weight. The final toxicity test was conducted with doses of 0, 7.50, 10.00, 11.25, 12.50, 13.75 and 15.00  $\text{mg}\cdot\text{kg}^{-1}$ . The doses were prepared by suspension of  $\text{AFB}_1$  in 0.1 ml of peanut oil. The  $\text{AFB}_1$ -peanut oil suspension was prepared by dissolving  $\text{AFB}_1$  in warm chloroform ( $1\text{mg}\cdot\text{ml}^{-1}$ ), and the volume required for different dose groups was transferred into a small vial. Required quantity of peanut oil per dose group was added and mixed thoroughly, and the chloroform was allowed to evaporate for 24 h. The fish were fasted for 24 h before administration of  $\text{AFB}_1$ . All fish were anaesthetized with MS-222 and injected intraperitoneally with required quantity of  $\text{AFB}_1$ -oil suspension based on their body weight. The trial was conducted in duplicate and the two pools in each dose group contained 15 numbers of fish in total. The injected fish were observed for 10 d for overt signs of toxicity and deaths. The 10-d  $\text{LD}_{50}$  value was determined following the method of Litchfield and Wilcoxon (1949).

The different levels for acute and subchronic trials were selected based on : (a)  $\text{LD}_{50}$  value of rohu fingerlings to  $\text{AFB}_1$  as observed here; (b) the age and weight of the test animals (Halver 1969; Bailey and Hendricks 1988); (c) the possible rapid metabolism of  $\text{AFB}_1$  by tropical fish (Bailey and Hendricks 1988). The fish were divided randomly into six groups for conducting acute and subchronic toxicity trials. Each group had 20 fish maintained equally in two aquaria. The fish were fed a pelleted diet for 15 d and then fasted for 24 h before administration of  $\text{AFB}_1$ . All fish were anaesthetized with MS 222 @  $0.15 \text{ g}\cdot\text{l}^{-1}$  (Sandoz) and were injected intraperitoneally (I/P) with 7.5 and 11.25 mg of  $\text{AFB}_1 \text{ kg}^{-1}$  body weight for the acute trial, and 1.25 and 2.5 mg of  $\text{AFB}_1 \text{ kg}^{-1}$  body weight for the subchronic trial. The control group fish of each trial received peanut oil injection (I/P) without  $\text{AFB}_1$ . The acute and subchronic trials were carried out for 10 and 90 days, respectively. As the preliminary trial of oral feeding of aflatoxin failed to estimate the exact intake of  $\text{AFB}_1$  per fish (because of frequent regurgitation of stomach contents), the I/P route was chosen in this study that would also avoid loss from leaching if administered through the feed. Above all, it is already known that the relative toxicity of  $\text{AFB}_1$  by intraperitoneal exposure has a 7.5 times higher toxicity than the oral exposure in fish (Bauer et al. 1969).

The gill and opisthonephros tissues of five fish from the control, and freshly dead (4 numbers within 5 days) or moribund (six numbers within 9

days of exposure) fish of toxin-treated groups of the acute trial, and 10 randomly selected fish from each treatment (five fish from each tank) of the subchronic trial and the control group were processed for necropsy. The tissue samples were fixed immediately in 10% phosphate-buffered formalin and were processed for light microscopy using standard methods. Paraffin embedded sections (5 $\mu$ m) were stained with haematoxylin and eosin for histopathological study.

Tissues collected were also used for transmission electron microscopy (TEM) immediately after anaesthetization with MS-222, sliced and minced (1 mm<sup>3</sup>) in chilled fixative (3% glutaraldehyde 0.1M in phosphate buffer, pH 7.2) and subsequently fixed in fresh fixative solution for 24 h at 4°C. These were washed in three changes of phosphate buffer solution for 30 min at 4°C, post-fixed in buffered (0.1M phosphate buffer, pH 7.2) 1% OsO<sub>4</sub> for 2 h at 4°C, dehydrated in graded series of acetone and infiltrated in araldite resin (CY-212, Polysciences, Inc, Warrington) oriented in flat embedding moulds. Semithin (1-2  $\mu$ m) sections from randomly selected blocks of each gill were cut and stained with toluidine blue for 30 s. Paraffin and semithin sections from each gill were examined. Ultrathin sections (60-70 nm) from not less than 3 selected blocks per gill were cut, mounted on copper grids, and stained with aqueous uranyl acetate and lead citrate. Stained sections were examined with a JEOL-TEMSCAN-100 CX II analytical electron microscope at 60 kv.

## Results

The 10-d LD<sub>50</sub> of AFB<sub>1</sub> given IP was 12.6 mg•kg<sup>-1</sup> of body weight, with a 95% confidence interval of 12-13.3 mg•kg<sup>-1</sup>. The slope (S) was 1.2 (Table 1). By 36 h post injection, some of the fish injected with doses of 11.25 mg•kg<sup>-1</sup> or higher were lethargic, had reduced feed intake and lost equilibrium. The mortality was marked from day 3 onwards up to 7th day. The fish injected with peanut oil alone (0 mg•kg<sup>-1</sup> or control group) did not show any mortality. There was no mortality in the subchronic trials or in the controls. The fish showed darkening of the body before death.

Table 1. Effect of different concentrations of aflatoxin B<sub>1</sub> on relative percent mortality in *Labeo rohita* fingerlings observed for 10 days. Lethal concentrations, slope function and 95 % confidence limits are expressed in mg•kg<sup>-1</sup> body weight.

Concentrations of AFB <sub>1</sub> (mg•kg <sup>-1</sup> body weight)	Dead/ tested	Mortality (%)	Lethal concentration (IP) mg•kg <sup>-1</sup> body weight at			Slope function (s)	95% confidence limit	
			16%	50%	84%		Lower	Upper
0	0/15	0						
7.5	3/15	20.0						
10.00	4/15	26.7						
11.25	5/15	33.3	7.9	12.6	19.1	1.2	12.0	13.3
12.50	6/15	40.0						
13.75	9/15	60.0						
15.00	12/15	80.0						

On necropsy, the damage to the gills of toxin-treated fish was not uniform. Some areas with severe damage could be seen adjacent to the unaffected areas. In the acute trials, the dead/moribund fish sometimes, revealed a pale colour in outer most parts of the second and third gill arches and red to brown colour in inner parts. Minute areas of haemorrhages or blood clots appeared on the gills of fish treated with 11.25 mg of AFB<sub>1</sub> kg<sup>-1</sup> body weight. The fish of subchronic dose groups had pale brown gills.

In the acute trial the aflatoxin injected groups revealed similar toxicity signs as described in LD<sub>50</sub> trial before death. However, no external and behavioural changes were observed during the experimental period in the subchronic trial. Grossly, the trunk kidneys of aflatoxin-treated fish collected from acute and subchronic trials were congested in comparison to control group.

Under light microscopy, gill tissues of control group fish appeared to be normal with single layer of epithelial cells covering the blood passage of secondary lamellae. In the acute trials, the lower dose-treated group of fish had mild secondary lamellar epithelial hyperplasia, moderate edema of the secondary lamellae rendering ballooning of the epithelia rendering epithelial lifting. The higher dose-treated group of fish revealed rupture of the lamellar capillaries with escape of red blood cells into the interlamellar space (Fig. 1). There was complete loss and necrosis of secondary lamellae at some places along with inflammatory reaction. Semithin sections showed degeneration of the lamellar epithelia and damage of the capillary membrane revealing escape of the blood cells distinctly (Fig. 2A). Most of the fish of the acute dose groups showed massive accumulation of eosinophilic granular cells (EGC) at the base of secondary lamellae alongwith hyperplasia and fusion of secondary lamellae (Fig. 2B) without changes in the pillar cells on the contrary to absence of EGC in control fish lamellae (Fig. 2C).

The fish in the subchronic trials revealed dose-related damage to the gills. The lamellar epithelial hyperplasia resulting in fusion was the most predominant feature (Fig. 2D). Many secondary lamellae showed fusion up to the tip forming distended capillary space at the extremity (Fig. 2D). Although the infiltration of eosinophilic granular cells and lamellar edema were evident, the degree of cellular reactions was lower in comparison to the acute trials. However, the general organization of the lamellar epithelium was altered in both the trials.

The control group fish of acute and subchronic trials had normal glomeruli and tubules along with presence of all type of haemopoietic cells, mostly of monocytoid series (Fig. 3). In acute study, the aflatoxin-treated fish



Fig. 1. Photomicrograph of gill lamellae of acute toxicity (@ 11.25 mg AFB<sub>1</sub> kg<sup>-1</sup>) showing edema and haemorrhages. Note blood cells (bc) lying in the inter-lamellar space due to rupture of the capillaries. (H & E). Bar = 32 mm.

revealed degrees of degenerative and necrotic changes in the tubular epithelium. The changes were dose dependent and more prominent in first proximal segments (Fig. 4). The trunk kidney showed degenerative and necrotic changes in the tubules along with accumulation of eosinophilic debris of the epithelial cells in the tubular lumen of aflatoxin-treated fish of subchronic toxicity. The interstitium also had focal necrotic nodules and nodules of pigment-laden cells.

In the electron microscopical observations, the secondary lamellae of the control group of fish arranged as rays on both sides of the primary lamellae, a layer of epithelial cells separated by pillar cells (Fig. 5). The blood cells were seen distinctly occupying the capillary space. The chloride cells were evident at the base of the secondary lamellae and the pillar cells were distinct with their characteristic large, centrally located nuclei. EGCs were hardly evident in the lamellae of control fish. In contrast, the gills of acute toxicity cases showed distinguishable ultrastructural changes. The epithelial cells of secondary gill lamellae had many protrusions extending between interlamellar spaces causing fusion of lamella, mostly upto two-third of their length from the origin (Fig.6). The other alterations observed in acute cases were shrunken hyperplastic epithelial cells amidst marked intracellular edema. The detachment of epithelial cells from the central capillaries was markedly evident (Fig. 7). The chloride cells showed mild degenerative changes. The cells in the lamellar epithelium of fish of subchronic toxicity showed more hyperplastic and edematous changes than acute toxicity.

On electron microscopy, the control kidneys of both the trials had normal glomerulus (Fig. 8), and brush boarder, and interstitial haemopoietic cells mostly of lymphocytic and monocytic series (Fig. 9). One typical structure was observed among the interstitial cells in control as well as toxin-treated groups which could not be identified presently (Fig. 9). In the acute trial, few glomerular mesangial cells showed hyperplastic changes (Fig. 10). The elongated



Fig. 2A. Semithin section of gill lamellae showing fusion of secondary lamellae and rupture of capillaries at the tip (arrow) of lamella releasing blood cells (Toluidine blue). Bar = 16 mm.



Fig. 2B. Semithin section showing lamellar fusion, epithelial hyperplasia and accumulation of eosinophilic granular cells (arrow) at the base of secondary lamellae (acute toxicity). (Toluidine blue). Bar = 16 mm.



Fig. 2C. Semithin section of control fish gill revealing normal looking individual gill lamellae without presence of eosinophilic granular cell at the base. (Toluidine blue). Bar = 12 mm.

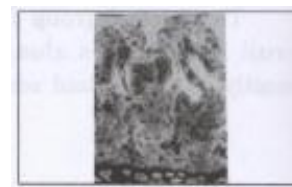

Fig. 2D. Semithin section showing epithelial hyperplasia, fusion upto the tip (arrow) and clubbing of secondary lamellae. (subchronic toxicity) (Toluidine blue). Bar = 16 mm.

mitochondria of tubular columnar epithelium were swollen with dilated cristae. There was modest increase in size of mitochondrion, and dilution of the matrix as evidenced by a decreased density. The proximal tubular epithelial cells were shrunken in few instances and revealed necrotic changes (Fig. 11). The telolysosomes containing different electron-dense masses were evident in few cells. The lumen of first proximal segment of renal tubule was filled with some amount of semielectron dense material. The striated boarder was less evident in the columnar epithelial cells of first proximal segment. Intra-cytoplasmic desmosomes were marked in many tubular basement membrane epithelial cells (Fig. 12). The interstitial space had more numbers of macrophages containing phagocytosed bodies. The lymphocytic cells were less

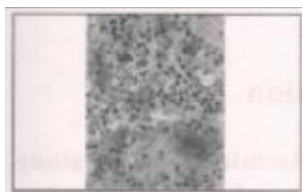


Fig. 3. Opisthonephros (posterior kidney) of control rohu (without aflatoxin injection) showing normal glomerulus (g), tubules (t) and haemopoietic cells of monocytoid series mostly. (Toluidene blue). Bar = 8 mm.



Fig. 4. Posterior kidney of acute toxicity group revealing degeneration and necrosis (arrow) of tubular epithelium. (Toluidene blue). Bar = 8 mm.



Fig. 5. Electronmicrograph of a gill tissue (control). Secondary lamellae showing central capillary (c), pillar cell (arrow) and surface epithelial cell (arrow head). Bar = 2.5 mm.

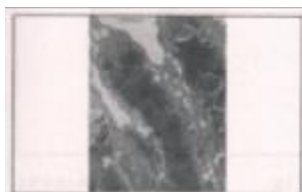


Fig. 6. Lamellar fusion upto two-third of their length in acute cases. Bar = 3.5 mm.

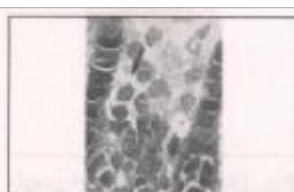

Fig. 7. Electron micrograph of gill from acute toxicity case revealing intraepithelial edema (arrow) and their separation from central capillaries along with hyperplasia. Bar = 3.5 mm.

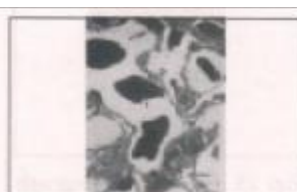

Fig. 8. Control fish glomerulus showing normal epithelial cells (arrow), mesangial cells (arrow head), red blood cells in the capillaries (r) and pedicels of podocytes (p). Bar = 3.5 mm.

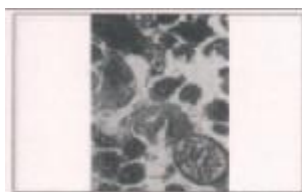

Fig. 9. Ultrastructure of interstitium of control fish kidney with abundant lymphocytes (L), macrophages (M) and probably one parasitic spore (P). Bar = 2.3 mm.



Fig. 10. Electron micrograph of acute toxin-treated group fish glomerulus showing hyperplasia of mesangial cells (arrow). Bar = 2.3 mm.

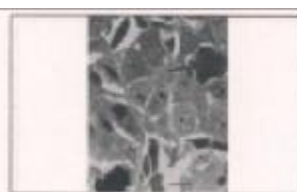

Fig. 11. Shrunken and necrotic (arrow) tubular epithelial cells from acute dose group fish: Electron micrograph (EM). Bar = 3.5 mm.

evident. The changes were more or less dose-dependent. In the subchronic trial, the aflatoxin-treated fish revealed various degrees of degenerative changes with increased numbers of swollen and elongated mitochondria (Fig. 13) the tubular epithelia. Similarly, telolysosomes of various forms containing different shapes of longitudinal, rectangular crystals of much more electron-dense within semi-electron dense mass occupying the major portion of cytoplasm were marked in the tubular epithelial cells (Fig. 14). Neutrophilic granulocytes (cytoplasm with dense rod-shaped core) were predominant cell type in the interstitial space (Fig. 15) alongwith numerous degraded cellular materials and necrotic haemopoietic cells forming nodules (Fig. 16). Occasionally, glomeruli were shrunken with hyperplasia of mesangial cells (Fig. 17). The pedicels of the podocytes were fused at many places (Fig. 18).

## Discussion

The IP LD<sub>50</sub> values determined in this study reflects the relative sensitivity of rohu to toxic levels of AFB<sub>1</sub>. The LD<sub>50</sub> (IP) of AFB<sub>1</sub> in rohu, 12.6 mg•kg<sup>-1</sup> of body weight, is nearly similar to the 11.5 mg•kg<sup>-1</sup> reported in channel catfish (Jantrarotai et al. 1990) and 16 times higher to

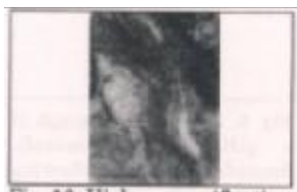

Fig. 12. Higher magnification of fig. 10 showing intacytoplasmic desmosome (d). EM. Bar = 0.33 mm.



Fig. 13. Electron micrograph of tubule of subchronic toxicity group: Note elongated, increased, swollen mitochondria (arrow head), degenerated epithelial cell (arrow) and semielectron dense mass inside lumen. Bar = 3.5 mm.

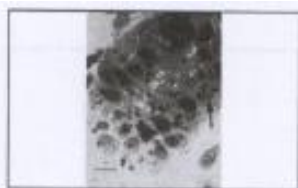

Fig. 14. Electron micrograph of tubule of subchronic toxicity group fish: Note presence of telolysosomes (arrow) of various forms containing crystalloid electron-dense structures inside semi-electron dense mass in the tubular epithelial cytoplasm. Bar = 3.5 mm.

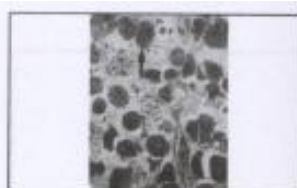


Fig. 15. Prominent neutrophilic granulocytes (arrow) in the interstitium of subchronic toxicity fish kidney. EM. Bar = 3.5 mm.

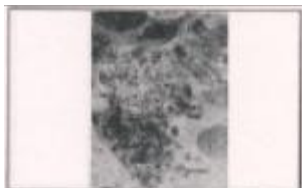

Fig. 16. Necrotic nodules and degraded cellular materials in the interstitium of subchronic toxicity group fish kidney. EM. Bar = 2.3 mm.



Fig. 17. Electron micrograph of glomerulus of kidney from subchronic toxicity fish: Note shrunken glomerulus with hyperplastic mesangial cells (arrow). Bar = 2.1 mm.

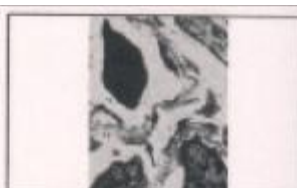

Fig. 18. Electron micrograph revealing fusion of pedicels of podocytes (arrow) in the glomerular loop of subchronic toxicity fish kidney. Bar = 1 mm.



the  $0.81 \text{ mg} \cdot \text{kg}^{-1}$  observed in rainbow trout (Bauer et al. 1969). This agrees with Halver's (1969) contention that doses of  $\text{AFB}_1$  causing acute aflatoxicosis vary among fishes, and that rohu is less sensitive than rainbow trout and channel catfish. Acute toxicity of  $\text{AFB}_1$  to fish is positively correlated to the ability of fish to reduce  $\text{AFB}_1$  to the more toxic metabolite aflatoxicol (AFL) by a cytoplasmic NADPH-dependent enzyme (Bailey and Hendricks 1988). Probably this enzyme is less active in rohu like channel catfish, making them less sensitive to  $\text{AFB}_1$  than are rainbow trout. Another possibility that the functional capacity of enzymes like glucuronyl transferase and sulfotransferase which transform xenobiotics into the excretory forms (Strength et al. 1982), might be more active in rohu. However, measurement of these enzymes of rohu in future will elucidate the possibility of mechanism of transformation of xenobiotics.

Rohu with acute aflatoxicosis were severely lethargic. Epithelial cells in rohu appear to be highly sensitive to the toxic effects of  $\text{AFB}_1$  because several lesions occurred in this cell type. Jantrarotai et al. (1990) also found similar increase susceptibility of epithelial cells in aflatoxin-treated channel catfish.

Histopathological and ultrastructural studies in cases of aflatoxin-treated fish indicated alterations in the gill tissue. Some of these changes have also been recorded by Ashley (1967) in aflatoxin treated trout. The lamellae of fish treated with aflatoxin showed a variety of changes at the cytological level. Owing to separation of the epithelial cells of lamellae as observed earlier in aflatoxicosis (Ashley 1967), the distance between the blood in the capillaries and the oxygen-containing water was increased. This may lead to an insufficient oxygen in the blood, unsatisfactory oxygen supply to the tissue, and lamellar necrosis. An inflammatory infiltration process was detected after massive necrosis of secondary lamellae, though gill structure was retained. We considered this pathology localised, rather than a generalized effect, since it occurred after severe and irreversible damage by aflatoxin to gill tissue. The extensive lamellar edema and epithelial vacuolization in this study reflected the changes in permeability at tissue level. Diffusional resistance, which is the major limiting factor for exchange across the gill is increased by above lamellar changes (Tuurala 1983). Hyperplasia of lamellar epithelium noticed in the present study has also been reported earlier (Ashley 1967) in the gill filamental surface of aflatoxin-fed rainbow trout. In addition, hyperplasia can also be caused by a variety of noxious agents, including heavy metals, pesticides, and phenols as well as high pH, heat stress and the presence of micro-organisms (Chevalier et al. 1985). The proliferation of the respiratory epithelium seems to be a common response of fish exposed to hazardous substances including aflatoxin and it has been suggested to be a protective mechanism of the body indicating structural and functional disorder of cell (Phromkunthong et al. 1997). Two different processes serve to occlude interlamellar spaces and to reduce the surface area available for gaseous exchange. Proliferation of the lamellar epithelium progressively reduced the depth of the interlamellar space. In this process, which is further referred to as secondary fusion and marked mostly in acute

cases, adjacent lamellae remained parallel (Fig. 6). Lamellar fusion also appeared to develop as a sequel to apposition (Primary fusion). Apposition occurred through different mechanisms, which reduced or obliterated the width of the interlamellar space. These included (a) collapse of lamellae at the tip into one another (Fig. 2C), (b) vaculative cellular changes and (c) lamellar epithelial cellular separation and edema. The massive surface area reduction observed due to lamellar hyperplasia and fusion might have resulted in reduced oxygen exchange and impaired ion regulation putting severe stress on fish alongwith other cellular changes leading to accumulation of eosinophilic granular cells at the base of primary lamellae. The relative absence of EGC at the base of the lamellae of control fish indicated the fish were held in favourable environment in spite of the daily removal of waste feed and faecal materials. Aflatoxin has cytotoxic and carcinogenic effects and thus various gill changes observed in the present acute and subchronic experimental cases may be regarded as only the preliminary changes preceding the cell alterations in major target organs like liver and kidney.

The trunk or excretory kidney had degenerative and necrotic changes in tubular epithelial cells and haemopoietic interstitium with shrunken glomeruli in acute and subchronic cases. The degree of changes are dose dependent. Chavez-Sanchez et al. (1994) also found increased cellularity of glomeruli with occasional epithelial crescents and few shrunken glomeruli surrounded by widened Bowman's space in aflatoxin-fed Nile tilapia. On the contrary, atrophic kidney was observed in crude aflatoxin-fed *Channa punctatus* (Verma et al. 1989).

Some typical changes are observed at ultrastructural levels in aflatoxin-treated fish. There is paucity of information on the ultrastructural changes in trunk kidney of fish of other animals due to aflatoxicosis from the available literature. The fish treated with aflatoxin exhibited alterations in the ultrastructure of the proximal tubules. Changes in the constitution of mitochondria in the epithelial cells of proximal tubules alongwith presence of intracytoplasmic desmosomes in basement membrane epithelial cells indicate damage due to toxic substances or carcinogenic chemical effects (Ghadially 1982 a, b). The presence of large numbers of telolysosomes (residual elements of autophagolysosomes) may be due to defect in the digestive apparatus of the lysosomes. The increase in autophagosomes has also been marked in hepatic cell of aflatoxin-fed guinea pigs (Thurston et al. 1980). Tandler and Rossi (1977) reported that the presence of large numbers of lysosomes in a human Chediak-Higashi syndrome might be due to disturbances in lysosomal production and function. The hyperplasia of mesangial cells as well as shrunken glomeruli observed in our study have also been reported in fish by earlier workers (Ashley 1965; Jantrarotai et al. 1990). The reduction of lymphocytic cells in interstitium of kidney of acute and subchronic cases might be due to lymphocytolysis caused by aflatoxin. Sahoo et al. (1996) and Tung et al. (1975) also attributed the reduction of lymphocyte population due to damage to lymphoid follicles in aflatoxin-treated rabbits and birds, respectively. In conclusion, the present study clearly reveals the susceptibility of rohu to aflatoxin as well as its nephrotoxic and cytotoxic nature in fish.

## Acknowledgements

The study is supported in part SERC visiting fellowship grant –SR/VS/10/97 by Department of Science and Technology, New Delhi, and by the Council of Scientific and Industrial Research, New Delhi. Thanks are due to the Director, Central Institute of Freshwater Aquaculture, Kausalyaganga, Bhubaneswar and Director, Institute of Pathology, New Delhi, India for providing the necessary facilities during this study. We thank Ms. A. Srivastava and Ms. A. Bhatia, Institute of Pathology, New Delhi for processing of the EM materials.

## References

- Ashley, L.M. and J.E. Halver. 1963. Multiple metastasis of rainbow trout hepatoma. Transactions of American Fisheries Society 92: 365 –371.
- Ashley, L. M. 1965. Histopathology of rainbow trout aflatoxicosis. In: Trout hepatoma research conference papers (eds J.E. Halver and I.A. Mitchel) U.S.D.H.E.W. and U.S.D. International Fish/Wildlife Research Report 70: 103 -120.
- Ashley, L.M., 1967. Histopathology of rainbow trout aflatoxicosis. In: Trout hepatoma research conference papers (eds. J.E. Halver and I.A. Mitchell), pp. 103-120. Bureau of Sport Fisheries and Wildlife, Washington.
- Bailey, G. and J.D. Hendricks. 1988. Environmental and dietary modulation of carcinogenesis in fish. Aquatic Toxicology 11: 69-75.
- Bauer, D. H., D. J. Lee and R. O. Sinnhuber. 1969. Acute toxicity of aflatoxin B<sub>1</sub> and G<sub>1</sub> in the rainbow trout (*Salmo gairdneri*). Toxicology and Applied Pharmacology 15: 415-419.
- Chavez-Sanchez, Ma. C., C. A. Martinez Palacios and I. Osorio Moreno. 1994. Pathological effects of feeding young *Oreochromis niloticus* diets supplemented with different levels of aflatoxin B<sub>1</sub>. Aquaculture 127: 49 –60.
- Chevalier, G., L. Gauthier and G. Morea. 1985. Histopathological and electron microscopic studies of gills of brook trout, *Salvelinus fontinalis*, from acidified lakes. Canadian Journal of Zoology 63: 2062 –2070.
- Ghadially, F. N. 1982a. Mitochondria. In : Ultrastructural pathology of the cell and matrix. 2nd edition. Butterworths, London. pp. 149-263.
- Ghadially, F.N. 1982b. Cytoplasmic matrix and its inclusions. In : Ultrastructural pathology of the cell and matrix, pp. 703-758. 2nd edition. Butterworths, London.
- Halver, J. E. , L.M. Ashley, and G.N. Wogan. 1966. Acute aflatoxicosis in rainbow trout and coho salmon. Federation Proceedings 27: 552.
- Halver, J.E. 1969. Aflatoxicosis and trout hepatoma. In: Aflatoxin Scientific background, control and implications (ed. L.A. Goldblatt), pp. 265-306. Academic Press, New York.
- Hendricks, J. D., T. P. Putnam, D.D. Bills and R.O. Sinnhuber. 1977. Inhibitory effect of a polychlorinated biphenyl (Aroclor 1254) on aflatoxin B<sub>1</sub> carcinogenesis in rainbow trout (*Salmo gairdneri*). Journal of National Cancer Institute 59 : 1545 –1551.
- Jantrarotai, W. and R.T. Lovell. 1990. Subchronic toxicity to dietary aflatoxin B<sub>1</sub> to channel catfish. Journal of Aquatic Animal Health 2 : 248-254.
- Jantrarotai, W., R.T. Lovell and J.M. Grizzle. 1990. Acute toxicity of aflatoxin B<sub>1</sub> to channel catfish. Journal of Aquatic Animal Health 2 : 237-247.
- Litchfield J.T. Jr. and F. Wilcoxon. 1949. A simplified method of evaluating dose effect experiments. Journal of Pharmacological Experiment Theory 96 : 99-113.
- Niyo, K. A. 1989. Mycotoxins : economic and health risks. Council for Agricultural Science and Technology, Ames, Iowa, Task force report no. 116.
- Phromkunthong, W., M. Boonyaratpalin and V. Storch. 1997. Different concentrations of ascorbyl-2- monophosphate-magnesium as dietary sources of vitamin C for seabass, *Lates calcarifer* . Aquaculture 151 : 225-243.
- Sahoo, P. K., S. K. Chattopadhyay and A. Sikdar. 1996. Immunosuppressive effects of induced aflatoxicosis in rabbits. Journal of Applied Animal Research 9 : 17-26.

- Sahoo, P. K., S. C. Mukherjee, S. K. Nayak and S. K. Dey. 2001. Acute and subchronic toxicity of aflatoxin B<sub>1</sub> in rohu (*Labeo rohita*). Indian Journal of Experimental Biology 39: 453-458.
- Sahoo, P.K. and S. C. Mukherjee. 2001. Immunosuppressive effects of aflatoxin B<sub>1</sub> in Indian major carp (*Labeo rohita*). Comparative Immunology, Microbiology & Infectious Diseases 24: 143-149.
- Shank, R. C. 1981. Mycotoxins and N-nitroso compounds: Environmental risks. 11 pp., CRC Press, Vol. II, Boca Raton, Florida.
- Sinnhuber, R.O. and J.H. Wales, 1974. Aflatoxin B<sub>1</sub>. Hepatocarcinogenicity in rainbow trout embryos. Federation Proceedings 33 : 247.
- Strength, D.R., D.V. Saradmbal, Sahoo -Liz Wang, H. H. Daron and W.P. Schoor. 1982. Glucuronosyl and sulfo-transferases in fish exposed to environmental carcinogens . Federation Proceedings 41 : 1147.
- Svobodova, Z. and A. Piskac. 1980. The effect of feed with a low content of aflatoxin B<sub>1</sub> on the health condition of carp (*Cyprinus carpio L.* ). Zivocisna Vyroba -UVTIZ 25 : 809 -814.
- Tandler, B. and E.P. Rossi. 1977. Granular cell ameloblastoma. : Electron microscopic observations. Journal of Oral Pathology 6 : 401.
- Thurston. J.R. , A.L. Baetz., N.F. Cheville and J.L. Richard. 1980. Acute aflatoxicosis in guinea pigs : Sequential changes in serum proteins, complements, C<sub>4</sub> and liver enzymes and histopathologic changes. American Journal of Veterinary Research 41: 1272-11276.
- Tung, H.T. , F.W. Cook, R.D. Wyatt and P.B. Hamilton. 1975. The anaemia caused by aflatoxin. Poultry Science. 54 : 1962-1970.
- Tuurala, H. 1983. Relationships between secondary lamellar structure and dorsal aortic oxygen tension in *Salmo gairdneri* with gills damaged by zinc. Annals de Zoologica Fennici 20 : 235-238.
- Verma, S. K., S. Pandey and R.A.B. Verma. 1989. Toxigenic fungi associated with fish rations and their effect on the histopathology of *Channa punctatus*. Biojournal 1 : 113-118.
- Wogan, G. N. 1966. Chemical nature and biological effects of the aflatoxins. Bacteriological Reviews. 30 : 460-470.