

# Prevalence and Histopathology of Monodon Baculovirus (MBV) Infection in *Penaeus monodon* and *P. indicus* in Shrimp Farms in the South-East Coast of India

K.K. VIJAYAN, S.V. ALAVANDI, K.V. RAJENDRAN and K. ALAGARSWAMI

Central Institute of Brackishwater Aquaculture  
141 Marshalls Road, Egmore  
Madras 600 008, India

**Abstract** - A 2-year survey (1993-95) on diseases of cultured shrimp *Penaeus monodon* and *P. indicus* in shrimp farms of Tamilnadu and Andhra Pradesh, South India, revealed a high prevalence of monodon baculovirus (MBV) infection. Secondary bacterial and epicomensal infections were also noted in many cases. Prevalence of MBV infection was found to be as high as 42% in a few localities. Characteristic histopathological changes in the hepatopancreas and lymphoid organ are described. This is the first detailed report of MBV infection from this geographical region, and the first that reports *P. indicus* as a new host of this baculovirus.

Monodon baculovirus (MBV) was first described by Lightner and Redman (1981) in *Penaeus monodon* from Taiwan. Since then it has been identified and reported in *P. merguensis*, *P. semisulcatus* and *P. kerathurus* (Johnson and Lightner 1988; Lightner 1988), and in *P. vannamei* (Lightner et al. 1990). *P. esculentus*, *P. penicillatus* and *P. plebejus* have also been reported as hosts of MBV (Lightner and Redman 1992). This virus appears to be enzootic in South-east Asia, though there have been no reports from the Indian subcontinent except a preliminary record by Alavandi et al. (1995).

Shrimp culture has become a fast-growing industry in India during the past decade. The environmental deterioration and disease outbreaks that are inevitable with the expansion and intensification of the industry, occur frequently in this geographical area. During a survey of bacterial, viral and parasitic diseases of shrimp in Tamilnadu and Andhra Pradesh coasts of India, the authors came across moderate to heavy infection of MBV in *P. monodon* and *P. indicus*.

Samples of *P. monodon* (4.0-40.0 g wet weight) and *P. indicus* (3.0-29.0 g wet weight) were collected in January 1993 through February 1995 from various shrimp farms in Tamilnadu and Andhra Pradesh, South-East coast of India, and brought alive to the laboratory in oxygen-packed polythene bags. Moribund shrimp were dissected immediately, and gills, hepatopancreas, lymphoid organ, body muscle and heart were fixed in Davidson's fixative or 10% Neutral Buffered Formalin (NBF). Tissue impression smears were prepared from fresh tissues and stained with 0.1% aqueous malachite green. Air-dried smears were fixed in 10% NBF and stained with hematoxylin-eosin (H&E).

For the histological studies, tissues fixed in Davidson's fixative for 24 h were transferred to 50% ethanol, and processed using routine histological techniques (Bell and Lightner 1988). Paraffin sections of 4-5  $\mu\text{m}$  thickness were stained with H&E and examined microscopically. Photomicrographs were taken using a WILD MPS46 microcamera fitted to a Leitz Laborlux S microscope.

The present survey revealed a high prevalence of MBV infection both in *P. monodon* and *P. indicus*. Of the shrimp examined, 310 out of 832 (37.25%) were infected with MBV (Table 1). In certain areas, the prevalence was as high as 42.22%. Prevalence of infection in *P. monodon* (38.0%) was almost similar to that of *P. indicus* (33.57%). Clinically, most of the shrimp were apparently healthy. A few showed physical weakness, anorexia, epicommensal protozoan fouling and occasional white spots on the shells.

Table 1. Prevalence of monodon baculovirus (MBV) infection in the shrimp farms of Tamilnadu and Andhra Pradesh, India.

Locality	Culture system	Species cultured	No. of samples	No. infected	Prevalence (%)
Chidambaranar	Semi-intensive	<i>Penaeus monodon</i>	81	34	41.97
		<i>P. indicus</i>	12	4	33.33
Ramnad	Improved extensive	<i>P. monodon</i>	12	5	41.66
Tanjore	Semi-intensive	<i>P. monodon</i>	45	19	42.22
Quaide-e-Milleth	Semi-intensive	<i>P. monodon</i>	90	29	32.22
		<i>P. indicus</i>	30	8	26.66
Nellore	Semi-intensive	<i>P. monodon</i>	360	148	41.11
		<i>P. indicus</i>	80	29	36.25
Prakasam	Improved extensive	<i>P. monodon</i>	45	16	35.55
Krishna	Improved extensive	<i>P. monodon</i>	30	8	26.66
		<i>P. indicus</i>	18	6	33.33
West Godavari	Improved extensive	<i>P. monodon</i>	18	2	11.11
Visakhapatnam	Semi-intensive	<i>P. monodon</i>	11	2	18.18

*Zoothamnium* sp. was the most common protozoan found among the diseased shrimp. Occasionally, when infection was heavy, affected shrimp displayed brownish gills. Histological sections showed the protozoan attached to the gill lamellae without any host response (Fig. 1). Stromal matrix cells of lymphoid organ showed extensive necrosis and degeneration (Fig. 2). Body muscle and heart appeared normal.

Tissue impression smears of hepatopancreas showed deeply stained, multiple, globular occlusion bodies 0.8-8.4  $\mu\text{m}$  (mean 3.5  $\mu\text{m}$ ) in diameter (Fig. 3). Formalin-fixed smears stained with H&E also showed eosinophilic occlusion bodies of MBV.

Focal to extensive necrosis was noticed in the tubular epithelium of the hepatopancreas. Single to multiple intranuclear, eosinophilic occlusion bodies were detected in the epithelial cells (Fig. 4). In certain portions of the necrotic area, the tubular lumen was filled with sloughed epithelial cell debris and viral occlusions (Fig. 5). Due to the enlarged, multiple occlusion bodies, the nuclei

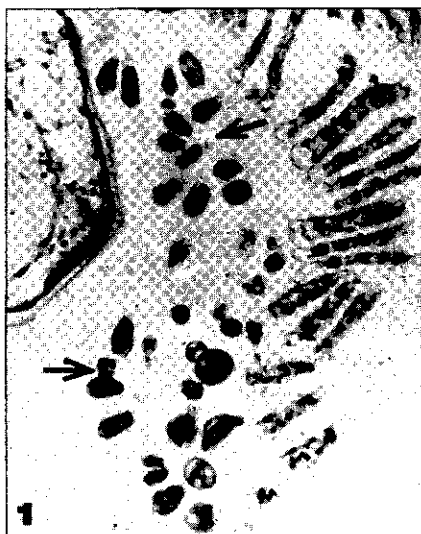

Fig.1. Histological section of gill showing epicommensal protozoan, *Zoothamnium* sp. (arrow) (H&E, X 100).

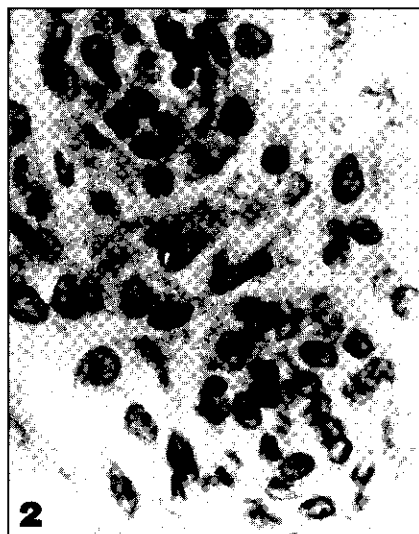

Fig.2. Histological section of lymphoid organ showing necrosis.

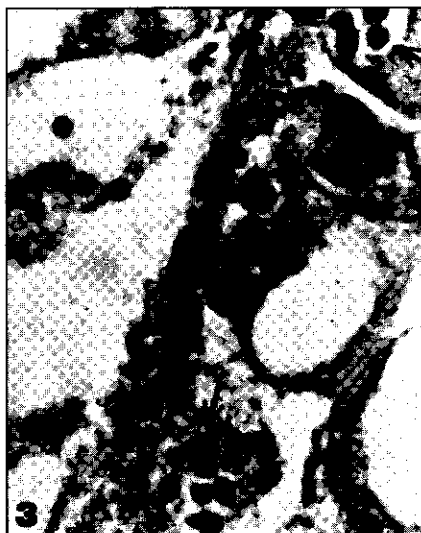

Fig.3. Tissue impression smear of hepatopancreas showing MBV occlusion bodies (arrow) (H&E, X 1,000).

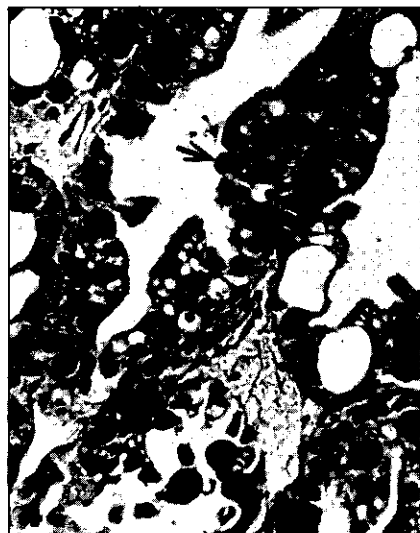


Fig.4. Histological section of hepatopancreas showing necrosis of tubular epithelium. Note the viral occlusions (arrow) (H&E, X 450).

appeared hypertrophied with fragmentation and margination of chromatin material (Fig. 6 and 7). In a few cells, the hypertrophied nuclei appeared as “signet rings” with peripherally displaced and compressed nucleolus (Fig. 8). Thus, hypertrophy of the nucleus with subsequent cellular destruction and desquamation of epithelial cells were the obvious histological changes. Inflammatory reactions with hemocyte infiltration and nodule formation were totally absent in all samples examined. Intertubular tissues were intact without necrotic or inflammatory changes.

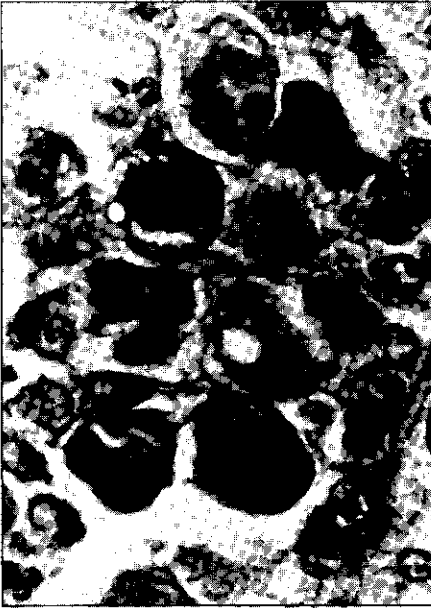

Fig.5. Enlarged view of a tubular lumen of hepatopancreas filled with sloughed epithelial cells and viral occlusions (H&E, X 1,000).

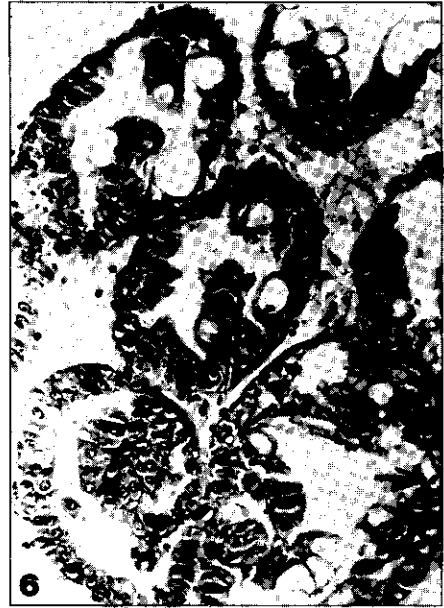

Fig.6. Hepatopancreatic tubules showing hypertrophied nuclei with marginated chromatin material (arrow) (H&E, X 250).



Fig.7. Enlarged view of the tubule showing the hypertrophied nucleus and viral occlusions (arrow) (H&E, X 1,000).

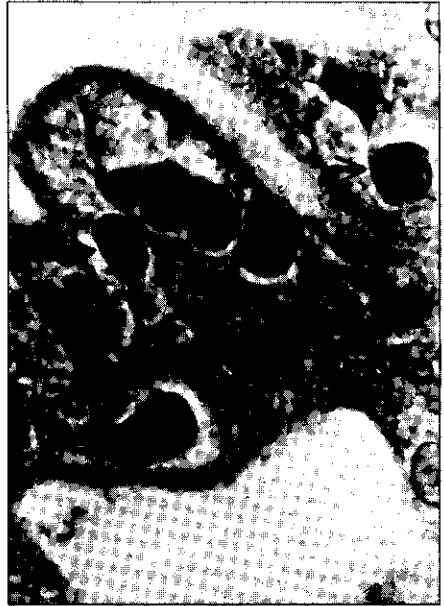

Fig.8. Enlarged view of the hypertrophied nuclei appearing as 'signet rings' (arrow) (H&E, X 1,000).

Shrimp infected with MBV appeared clinically normal though histopathological changes and the presence of intranuclear occlusion bodies in the hepatopancreas confirmed MBV infection. Similar characteristic histological changes due to MBV infection have previously been diagnosed and reported by Lightner and Redman (1981), Lightner et al. (1983), Nash et al. (1988) and Turnbull et al. (1994). In spite of marked focal to extensive necrosis in the hepatopancreas, there were no obvious signs of cellular or inflammatory reactions leading to hemocytic encapsulation and melanization. This may be due to the ability of MBV to mimic the host's protein in order to evade the host's defense response leading to a coexistence of host and pathogen; or due to the fact that MBV is intracellular, and therefore inaccessible to recognition by the host's defense mechanism until the necrosis of the infected host cell. Then, necrotic cellular debris and MBV virions and occlusions are in the hepatopancreas and/or gut lumen and rapidly excreted. Hence, the host defense mechanism may lack the opportunity to respond to the presence of MBV.

In most of the shrimps, *Zoothamnium* sp. was the predominant protozoan epicomensal causing fouling of gills and surface. However, no relationship between the parasite and MBV could be ascertained.

Geographic distribution of MBV in cultured penaeid shrimps and their natural and experimental host species have been documented by Lightner (1985) and later updated by Lightner and Redman (1992). The present report of MBV forms the first detailed record of this pathogen from the shrimp farming areas of India. Further, *P. indicus* is being reported as a new host species for this baculovirus.

Pathogenicity of MBV needs to be unequivocally established. MBV infections have been reported to be well tolerated by shrimp if other culture conditions are optimal (Lightner et al. 1987; Fegan et al. 1991). Natividad and Lightner (1992) reported that MBV infections would increase the susceptibility of shrimp to secondary infection. Cases of heavy mortality of shrimp in Taiwan and Thailand due to MBV have also been reported by Lin (1989), Tangtongpiroj (1989) and Thikiew (1990). Considering these factors, and the deteriorating culture conditions in many of the farms, this highly prevalent pathogen can become a major predisposing factor leading to catastrophic mortalities.

### Acknowledgments

Authors are grateful to the shrimp farm personnel for their help in providing facilities and specimens.

### References

- Alavandi, S.V., K.K. Vijayan and K.V. Rajendran. 1995. Shrimp diseases, their prevention and control. Central Institute of Brackishwater Aquaculture (CIBA) Bulletin 3: 1-17.
- Bell, T.A. and D.V. Lightner. 1988. A handbook of normal shrimp histology. World Aquaculture Society, Baton Rouge, Louisiana. 114 pp.
- Fegan, D.F., T.W. Flegel, S. Sriurairatana and M. Waiyakrutha. 1991. The occurrence, development and histopathology of monodon baculovirus in *Penaeus monodon* in Southern Thailand. Aquaculture 96: 205-217.

- Johnson, P.T. and D.V. Lightner. 1988. Rod-shaped nuclear viruses of crustaceans: gut-infecting species. *Diseases of Aquatic Organisms* 4: 123-141.
- Lightner, D.V. and R.N. Redman. 1981. A baculovirus-caused disease of the penaeid shrimp, *Penaeus monodon*. *Journal of Invertebrate Pathology* 38: 299-302.
- Lightner, D.V., R.M. Redman and T.A. Bell. 1983. Observations on the geographic distribution, pathogenesis and morphology of the baculovirus from *Penaeus monodon* Fabricius. *Aquaculture* 32: 209-233.
- Lightner, D.V. 1985. A review of the diseases of cultured penaeid shrimps and prawns with emphasis on recent discoveries and developments. Proceedings of the First International Conference on the Culture of Penaeid Prawns/Shrimps, Iloilo City, Philippines: 79-103.
- Lightner, D.V., R.P. Hedrick, J.L. Fryer, S.N. Chen, I.C. Lia and G.H. Kou. 1987. A survey of cultured penaeid shrimps in Taiwan for viral and other important diseases. *Fish Pathology* 22: 127-140.
- Lightner, D.V. 1988. Diseases of cultured penaeid shrimps and prawns. In: Disease diagnosis and control in North American marine aquaculture (eds. C.J. Sindermann and D.V. Lightner), pp. 8-127. Elsevier, Amsterdam.
- Lightner, D.V., T.A. Bell and R.M. Redman. 1990. A review of the known hosts, geographic range and current diagnostic procedures for the virus diseases of cultured penaeid shrimps. *Advances in Tropical Aquaculture*. Tahiti, AQUACOP, IFREMER, Centre de Brest, Plouzane, France. Actes de Colloque 9: 113-126.
- Lightner, D.V. and R.M. Redman. 1992. Penaeid virus diseases of the shrimp culture industry of the Americas. In: *Marine shrimp culture: Principles and practices* (eds. A.W. Fast and L. James Lester), pp. 569-588. Elsevier, Amsterdam.
- Lin, C.K. 1989. Prawn culture in Taiwan. What went wrong? *World Aquaculture* 20: 19-20.
- Nash, G., A. Poemomo and M.B. Nash. 1988. Baculovirus infection in brackishwater pond cultured *Penaeus monodon* Fabricius in Indonesia. *Aquaculture* 73: 1-6.
- Natividad, J.M. and D.V. Lightner. 1992. Susceptibility of the different larval and postlarval stages of the black tiger prawn, *Penaeus monodon* Fabricius, to *Monodon baculovirus* (MBV). In: *Diseases in Asian aquaculture I* (eds. M. Shariff, R.P. Subasinghe and J.R. Arthur), pp. 111-125. Fish Health Section, Asian Fisheries Society, Manila.
- Tangtongpiroj, J. 1989. A virus disease of black tiger prawn. *Fisheries News* 13(7): 25-29.
- Thikiew, N. 1990. A serious MBV outbreak in the black tiger prawn. *Livestock Production Magazine* 7(151): 13-16.
- Turnbull, J.F., P.E. Larkins, C. Mc Padden and R. Matondang. 1994. Histopathological disease survey of cultured shrimps in North-East Sumatra, Indonesia. *Journal of Fish Diseases* 17: 57-65.